International Journal of Biological Macromolecules 52 (2013) 66–71

Contents lists available at SciVerse ScienceDirect

International Journal of Biological Macromolecules

journal homepage: www.elsevier.com/locate/ijbiomac

Evaluation of in vivo antioxidant activity of *Hericium erinaceus* polysaccharides

Zi-Hua Han, Jian-Min Ye, Guan-Fu Wang*

Department of Urology, Luqiao Hospital of Taizhou Enze Medical Center (Group), Taizhou, Zhejiang Province 318050, PR China

ARTICLE INFO

Article history:
Received 15 August 2012
Received in revised form 3 September 2012
Accepted 11 September 2012
Available online 19 September 2012

Keywords:
Hericium erinaceus polysaccharides
Kidney
Ischemia reperfusion
SOD
HPLC
Antioxidant

ABSTRACT

Hericium erinaceus polysaccharide (HEP) is a traditional Chinese medicine. In the present study, chemical composition and antioxidant activity of HEP was investigated. HPLC analysis showed that the HEP was composed of xylose (7.8%), ribose (2.7%), glucose (68.4%), arabinose (11.3%), galactose (2.5%) and mannose (5.2%). HEP was pre-administered to mice by gavage at a dose of 300 mg/kg for 15 days. Results found that HEP preadministration resulted in a significant decline in blood urea nitrogen (BUN), serum creatinine (Scr) and increase in creatinine clearance (CrCI) levels in HEP-pretreated group compared to renal ischemia reperfusion (IR) group. Malondialdehyde (MDA) level significantly increased, whereas Level of reduced glutathione (GSH) markedly decreased in renal IR animals. These results indicate that IR induced renal oxidative injury damage, as indicated by a increase in MDA level, and decrease in GSH level as well as the antioxidant enzymes activity. Such effects reflect that HEP can significantly decrease lipid peroxidation level and increase antioxidant enzymes activities in experimental animals.
© 2012 Elsevier B.V. All rights reserved.

1. Introduction

Ischemia followed by reperfusion is a frequent clinical problem especially in cardiovascular surgery. Reperfusion injury is an inevitable consequence of the surgical intervention to relieve ischemia caused by acute arterial occlusion. Injury is not only limited to organs involved but also involve in distant organs [1]. Renal ischemia/reperfusion injury which occurs during renal transplantation, shock, and kidney resections, is a major cause for acute renal failure with increased morbidity and mortality. It has been estimated that ischemic insult, especially during renal transplantation, is responsible for 20–30% primary graft dysfunction [2]. Reperfusion of ischemic renal tissue initiates a complex series of cellular events that eventually leads to necrotic and apoptotic renal cell death.

The free radicals normally generated during the normal body metabolic pathways and also they can be acquired from the environment also. Free radicals contain unpaired electrons. The oxygen radicals, such as superoxide radical (O_2^-), hydroxyl radical ($^{\bullet}OH$) and non free radical species, such as hydrogen peroxide (H_2O_2) and singlet oxygen ($^{\bullet}O_2$), are generated in many redox processes of normal physiochemical pathways [3,4]. Antioxidant defense system comprising different enzymes such as superoxide dismutase, catalase and glutathione peroxidize trap and destroy these free radicals. Vitamin deficiency together with overproduction of free radicals and a reduced level of above mentioned enzymes is considered as the main culprit for producing oxidative stress [4].

Hericium erinaceus is a traditional Chinese medicine. Many studies have been performed for examining its pharmacological function in renal diseases. So, the present study aimed to evaluate the possible effect of *H. erinaceus* polysaccharides against oxidative injury in kidney IR animals.

2. Materials and methods

2.1. Preparation of H. erinaceus polysaccharides

H. erinaceus (300 g) was heated with 6 L deionized water, at reflux, for 2 h. The mixture was cooled to room temperature and filtered through Whatman No. 4 filter paper. The retentate was concentrated to a small volume and then mixed with 3 volumes of 95% ethanol to yield a 70% ethanolic solution. The precipitate thus obtained was lyophilized and ground to obtain a coarse powder of hot water extracted polysaccharides (80 g).

2.2. High-performance liquid chromatography (HPLC) analysis

Polysaccharides were hydrolyzed, and the released monosaccharides were separated and quantified by an HPLC method [5,6]. Briefly, 20 mg of HEP were hydrolyzed to monosaccharides by the addition of 2 mL of 3 M TFA. Monosaccharides were labeled with PMP by adding 50 μL of 0.5 M PMP solution in methanol and 50 μL of 0.3 M NaOH, vortexing, and incubating at 60 °C for 1 h. The resulting mixture was neutralized with 50 μL of 0.3 M HCl, and extracted with chloroform (1 mL). The process was repeated three times,

* Corresponding author. Tel.: +86 0576 82421047.
E-mail address: wanggf04@yeah.net (G.-F. Wang).

0141-8130/$ – see front matter © 2012 Elsevier B.V. All rights reserved.
http://dx.doi.org/10.1016/j.ijbiomac.2012.09.009

and then the aqueous layer was filtered through a 0.45-μm membrane for HPLC analysis at 250 nm. The analysis was carried out on a Shimadzu LC-2010A HPLC system equipped with a quaternary gradient pump unit, a UV–vis detector and an autosampler. The analytical column used was a RP-C18 column (4.6 mm × 250 mm i.d., 5 μm; Venusil, GS-Tek, Newark, DE). Elution was carried out at a flow rate of 1.0 mL/min at 35 °C. The mobile phase A consisted of acetonitrile and mobile phase B was 0.045% KH_2PO_4–0.05% triethylamine buffer (pH 7.0) using a gradient elution of 90–89–86% B by a linear decrease from 0–15–0 min. The injection volume was 20 μL.

2.3. Animals and groups

Wistar rats were bred in the animal house of our hospital, were used. The animals were maintained under normal conditions (12 h light/dark cycle) and were fed with pelleted standard laboratory mice feed and tap water.

Sixty wistar were randomly divided into three groups: sham operation (SO) group (n = 20); IR group (n = 20); HEP (300 mg/kg) + IR group (n = 20). Rats were orally administered HEP extract (300 mg/kg BW) or a control vehicle (saline) daily for 15 days, then subjected to 30 min of renal ischemia. Rats were anaesthetized with ether and right renal vascular pedicles were exposed via a midline laparotomy. Following unilateral renal ischemia (30 min) and reperfusion (30 or 60 min), nephrectomy was performed and kidneys were stored at −30 °C until analysis. In ischemia group, the kidneys were removed 30 or 60 min after of ischemia. Animals in sham operation group underwent a surgical procedure similar to the other groups but the artery was not occluded. After this period and under anesthesia, blood was obtained to determine plasma BUN, Scr and CrCI levels and antioxidant enzymes activities. Kidneys were removed either for histology, or antioxidant enzymes activities.

2.4. Enzymes activities assay

The activities of BUN, Scr and CrCI were measured using commercial kits following the manufacturer's instructions.

Lipid peroxidation was determined by the formation of thiobarbituric acid reactive substances (TBARS) according to the method of Ledwozyw et al. [7]. Malondialdehyde is formed as an end product of lipid peroxidation which reacts with TBA reagent under acidic condition to generate a pink colored product. Supernatant (0.1 mL) was added to 0.4 mL of distilled water, followed by the addition of 2.5 mL of trichloroacetic acid (TCA) and later left at room temperature for 15 min. TBA (1.5 mL) was then added and heated in a water bath at 100 °C for 30 min until a faint pink color was obtained. After cooling, the color was extracted in 1 mL of butanol and the intensity was measured using the spectrophotometer at EX 515 nm and EM 553 nm. 1,1,1,3-Tetraethoxypropane (Sigma, USA) was used as the standard.

GSH was estimated by a colorimetric method using Ellman's reagent as described by Sedlak and Lindsay [8]. An aliquot of the homogenate was deproteinized by addition of an equal volume of 4% sulfosalicylic acid and after centrifugation at 17,000 × g for 15 min at 2 °C. 0.5 mL of the diluted supernatant was added to 4.5 mL of Ellman's reagent. A blank was prepared with 0.5 mL of the diluted precipitate solution (diluted twice with 0.1 mL phosphate buffer and 4.5 mL Ellman's reagent). GSH was proportional to the absorbance at 412 nm. The GSH level was quantified using a standard curve prepared by plotting with different concentration of GSH.

Superoxide dismutase (SOD) was assayed by following the method of Misra and Frisovich [9,10]. Required amount (100 μL) of homogenate was added to tubes containing 0.5 mL of carbonate buffer and 0.5 of EDTA solution. The final volume was made up to 2.5 mL. The reaction was initiated by the addition of 0.5 mL of epinephrine and increase in absorbance at 480 nm was measured in a Systronics 119 UV spectrophotometer. One hundred percent auto oxidation of epinephrine to adrenochrome was performed in a control tube without the enzyme. The enzyme unit of activity was defined, as the enzyme required for 50% inhibition of epinephrine autooxidation.

Catalase activity was determined according to Aebi [11] by monitoring the decomposition of H_2O_2. In 1 mL of reaction mixture contain potassium phosphate buffer (pH 7.0), 250 μL of enzyme extract and 60 mM H_2O_2 to initiate the reaction. The reaction was measured at 240 nm for 3 min and H_2O_2 consumption was calculated using extinction coefficient, 39.4 mM^{-1} cm^{-1}.Glutathione peroxidase (GSH-Px) activity was determined by measuring the oxidation of NADPH at 22 °C [12,13]. The assay medium (3 mL) consisted of 1 mM of reduced glutathione, 0.15 mM NADPH, 0.15 mM H_2O_2, 40 mM potassium phosphate buffer (pH 7), 0.5 mM EDTA, 1 mM NaN_3, 1.5 units of glutathione reductase, and 300 mL of tissue extract. Absorbance at 340 nm was recorded over 3 min. An extinction coefficient of 6300 M^{-1} cm^{-1} was used for calculation of NADPH concentrations. One unit of GSH-Px was defined as the amount of extract required to oxidize 1 mmol of NADPH per min at 22 °C.

Glutathione reductase (GR) activity was assayed as described by Calberg and Mannervik [14], with some modifications, by measuring the oxidation of NADPH at 340 nm. The reaction mixture consisted of 0.1 M sodium phosphate buffer (pH 7.5), 1 mM EDTA, 0.63 mM NADPH and 0.15 mM GSSG.

2.5. Morphologic studies

Renal biopsies were obtained at 24 h of reperfusion, fixed in 4% buffered paraformaldehyde, and embedded in paraffin wax. Four-micron sections stained with hematoxylineosin and periodic acid-Schiff (PAS) were analyzed by light microscopy. Lesions were scored following these criteria: (1) mitosis and necrosis of individual cells; (2) necrosis of all cells in adjacent proximal convoluted tubules with survival of surrounding tubules; (3) necrosis confined to the distal third of the proximal convoluted tubule with a band of necrosis extending across the inner cortex; and 4, necrosis affecting all three segments of the proximal convoluted tubule [10].

2.6. Statistical analysis

Data was statistically evaluated using one-way ANOVA in SPSS version 11.5 installed computer. The values were considered significant when (p < 0.05).

3. Results

Ultraviolet spectroscopy analysis showed that absorption was not found in at 280 nm (Fig. 1). This indicated that protein had been eliminated from polysaccharides. The results showed that the isolated HEP consisted of carbohydrate and phenolics. HPLC analysis showed that the HEP was composed of xylose (7.8%), ribose (2.7%), glucose (68.4%), arabinose (11.3%), galactose (2.5%) and mannose (5.2%) (Table 1).

As shown in Fig. 2, the IR treatment resulted in significant increase of serum BUN and Scr levels (p < 0.01) and decrease of serum CrCI levels (p < 0.01) in IR group in respect to sham control. On the contrary, HEP pretreatment for 15 days led to significant (p < 0.01) decrease of serum BUN and Scr levels (p < 0.01) and increase of serum CrCI levels (p < 0.01) in HEP + IR group compared to IR group (Fig. 2). Moreover, the effect was more obvious in 30 min reperfusion than that in 60 min reperfusion.

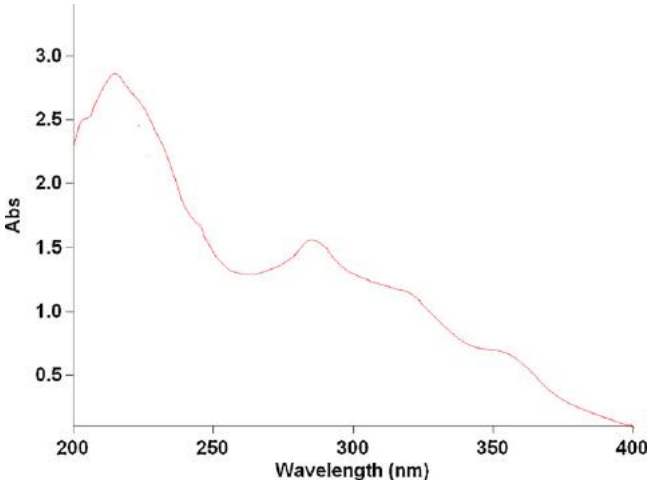

Fig. 1. Ultraviolet spectrum of HEP.

As shown in Fig. 3, the IR treatment resulted in significant increase of serum and renal MDA level ($p < 0.01$) in IR group in respect to sham control. On the contrary, HEP pretreatment for 15 days led to significant ($p < 0.01$) decrease of serum and renal MDA level in HEP + IR group compared to IR group (Fig. 3). Moreover, the effect was more obvious in 30 min reperfusion than that in 60 min reperfusion.

Table 1
Chemical composition of *Hericium erinaceus* polysaccharides.

Monosaccharide	Content
Xylose	7.8%
Ribose	2.7%
Glucose	68.4%
Arabinose	11.3%
Galactose	2.5%
Mannose	5.2%

The level of GSH in the serum and renal tissue of IR group was decreased significantly compared to sham control group (Fig. 4). Pretreatment of HEP for 15 days significantly reversed the fall in the levels of the above parameter in the serum and renal of HEP + IR group compared to IR group. With increasing reperfusion time, protective effect of HEP pretreatment against kidney IR-induced injury was weaken.

The activities of antioxidant enzymes (SOD, CAT, GSH-Px and GR) in serum and renal of IR group were significantly decreased as compared to sham control group (Figs. 5 and 6). HEP pretreatment for 15 days caused a significant reversal of the fall in the activities of

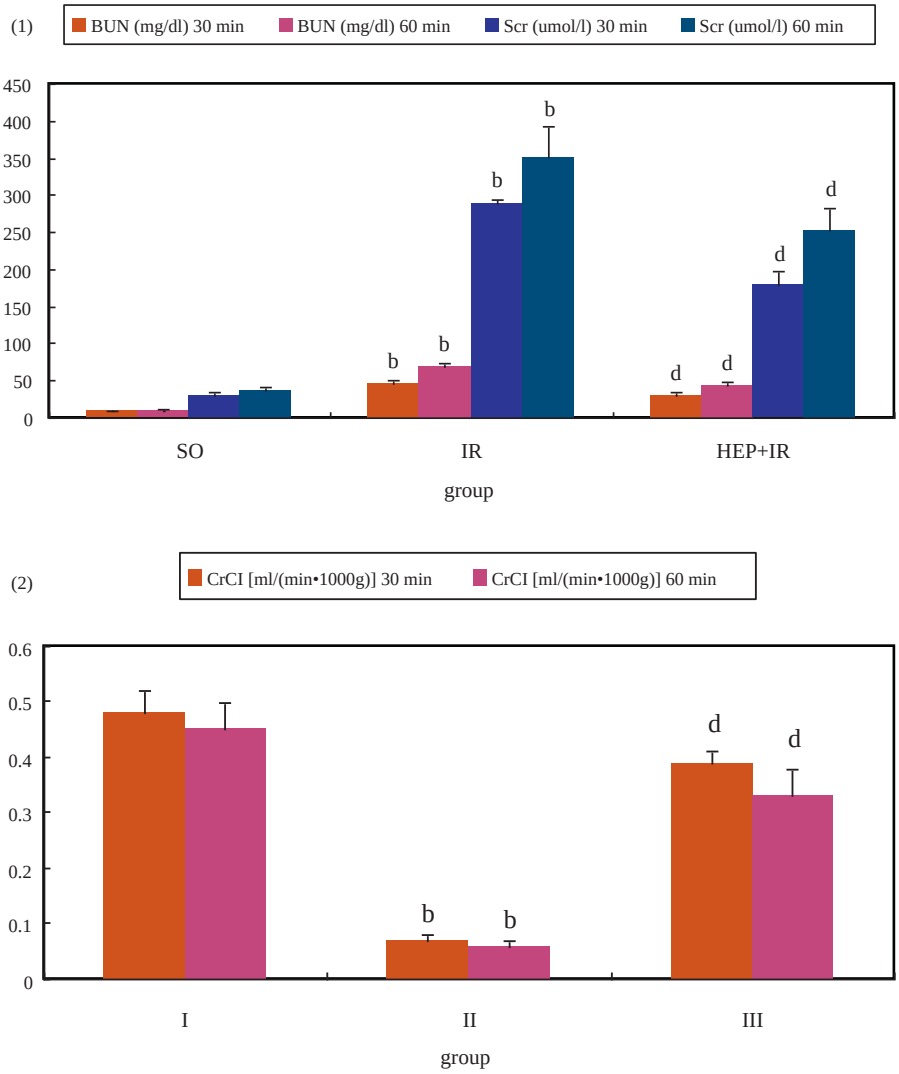

Fig. 2. (1) Effect of HEP on serum BUN, Scr and (2) CrCI levels in animals.

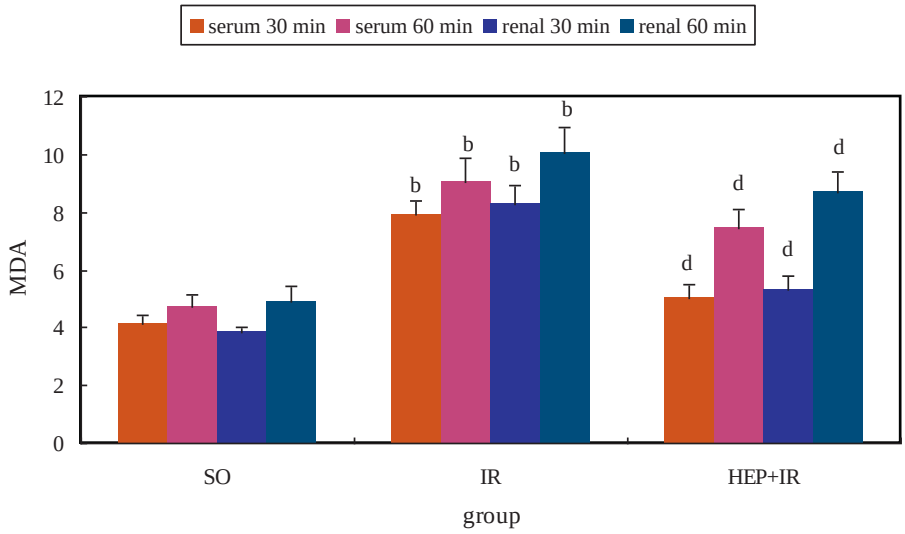

Fig. 3. Effect of HEP on serum and renal MDA levels in animals.

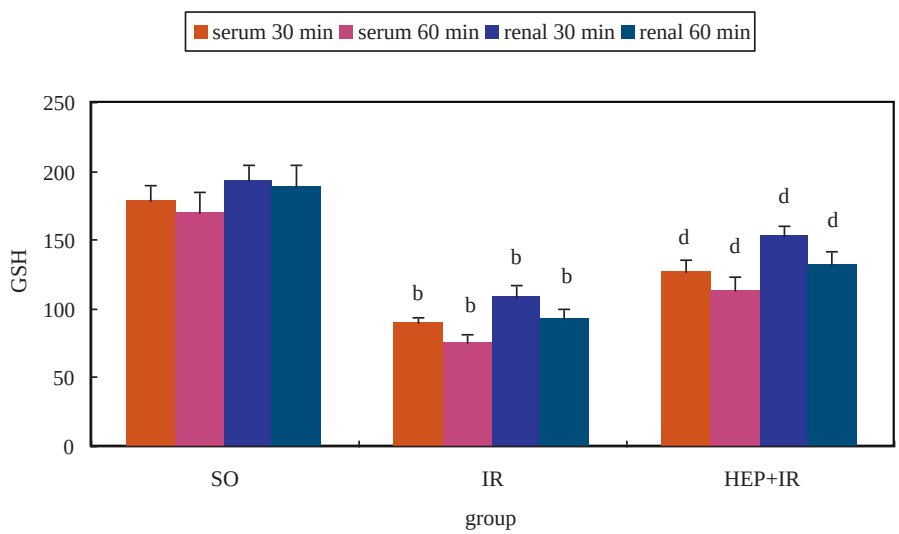

Fig. 4. Effect of HEP on serum and renal GSH levels in animals.

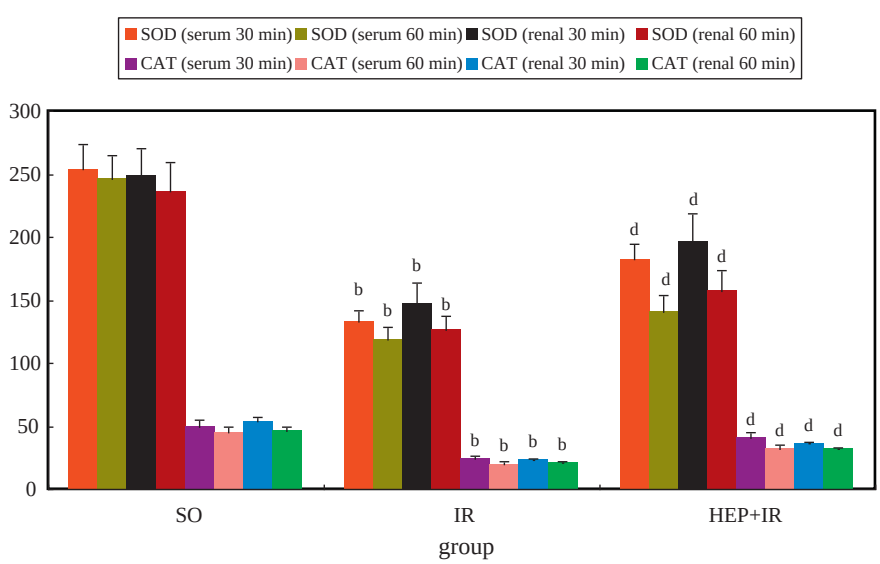

Fig. 5. Effect of HEP on serum and renal SOD and CAT activities in animals.

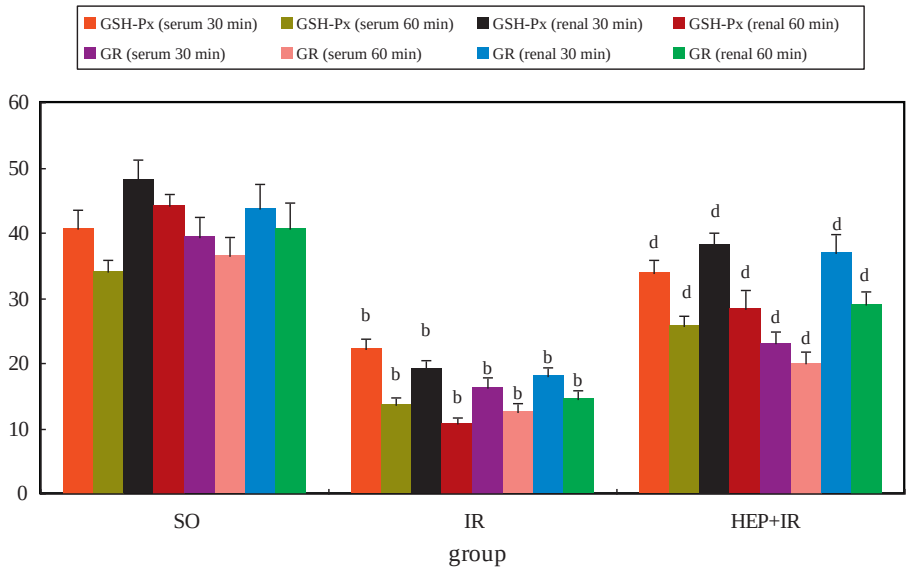

Fig. 6. Effect of HEP on serum and renal GSH-Px and GR activities in animals.

SOD, CAT, GSH-Px and GR in the serum and renal of HEP + IR group compared to IR group. In addition, antioxidant enzyme activities in animals receiving 30 min reperfusion were lower than corresponding values in animals receiving 60 min reperfusion.

The histopathologic changes were analyzed. The Sham group did not show any morphologic changes. In contrast, the section of kidneys obtained from untreated animals that underwent renal I/R demonstrated the recognized features of severe acute tubular damage. These features included tubular cell swelling, atypical regeneration, loss of brush border, hydropic degeneration, picnotic nuclei, tubular dilatation, and moderate to severe necrosis. Treatment with HEP preserved the normal morphology of the kidney demonstrating normal glomeruli and slight edema of the tubular cells.

4. Discussion

Acute renal failure produced by ischemia and reperfusion is a clinical and experimental syndrome characterized by a major reduction in glomerular filtration rate, extensive tubular damage, tubular cell necrosis, glomerular injury, and signs of tubular obstruction with cellular debris [15–17]. Much of tubular and glomerular dysfunction has been postulated to occur during the reperfusion period following ischemia, during which the generation of oxygen free radicals contributes to reperfusion injury.

In the present study, it was observed that animals with kidney IR caused a marked increase of serum BUN, Scr and MDA levels ($p < 0.01$) and decrease of serum CrCl levels ($p < 0.01$) in IR animals. These suggest severe oxidative injuries to renal tissue in experimental animals. Pretreatment with HEP displayed a beneficial effect. Membrane lipid peroxidation is an important pathophysiological event in a variety of diseases and stress conditions. MDA is a major reactive aldehyde produced from the peroxidation of polyunsaturated fatty acid present in the biological membranes [18]. IR injury has been attributed to ROS-mediated lipid peroxidation, which can be estimated by measuring the concentration of by-products such as MDA [19]. In the present study, HEP pretreatment significantly reduced MDA levels in the serum and kidney. Thus, HEP pretreatment may diminish renal IR injury by decreasing ROS levels and reducing oxidative damage.

Biological systems protect themselves against the damaging effects of activated species by several means. These include free radical scavengers and chain reaction terminators; enzymes such as SOD, CAT and GSH-Px system [20]. GSH along with other endogenous antioxidants such as ascorbic acid and α-tocopherol plays a central role in eliminating free radicals and other reactive species. Antioxidant activities of GSH are mainly attributed to its side chain sulfhydryl (—SH) residue.

Studies have reported that antioxidants such as erdosteine and mesna are able to improve renal injury after I/R [21,22]. Moreover, vitamin C (ascorbic acid), vitamin E, and a-lipoic acid have been reported to reduce renal I/R injury in animal models [23–26], suggesting that antioxidative agents may be a useful therapeutic approach for I/R injury.

In this study IR treatment inhibits the activities of antioxidant enzymes; CAT, GSH-Px, SOD, and GR and depletes the cellular GSH contents. The CAT, GSH-Px, GR and SOD activity was brought to increase by the treatment of HEP to animals. Pretreatment of HEP possibly inhibited the accumulation of IR-induced free radicals, decreased the oxidative stress and protected the antioxidant enzymes of kidney as revealed by the enhanced level of CAT, GSH-Px, GR and SOD in this experiment. In addition, protective effect of HEP pretreatment against IR-induced kidney oxidative injury was weaker in 60 min reperfusion than that in 30 min reperfusion. This indicated that renal-protective effect of HEP pretreatment was closely associated to reperfusion time.

5. Conclusion

It can be concluded that HEP display strong antioxidant activity and decreased IR-induced oxidative injury in kidney of experimental animals.

References

[1] D.L. Carden, D.N. Granger, Journal of Pathology 190 (2000) 255–266.
[2] R.J. Ploeg, J.H. van Bockel, P.T. Langendijk, M. Groenewegen, F.J. van der Woude, G.G. Persijn, J. Thorogood, J. Hermans, Lancet 340 (1992) 129–137.
[3] I. Martin, M.S. Grotewiel, Mechanisms of Ageing and Development 127 (2006) 411–423.
[4] M.S. Kataki, M.Z. Ahmed, D. Awasthi, B. Tomar, P. Mehra, R.S. Yadav, P. Rajak, Pharmacologia 3 (2012) 75–83.
[5] Y. Lv, X.B. Yang, Y. Zhao, Y. Ruan, Y. Yang, Z.Z. Wang, Food Chemistry 112 (2009) 742–746.
[6] N.W. He, X.B. Yang, Y.D. Jiao, L.M. Tian, Y. Zhao, Food Chemistry 133 (2012) 978–989.

[7] A. Ledwozyw, J. Michalak, A. Stepien, A. Kadziolka, Clinica Chimica Acta 155 (1986) 275–283.
[8] J. Sedlak, R.H. Lindsay, Analytical Biochemistry 25 (1968) 192–205.
[9] H.Z. Huo, B. Wang, Y.K. Liang, Y.Y. Bao, Y. Gu, International Journal of Molecular Sciences 12 (2011) 6529–6543.
[10] H.P. Misra, I. Frisovich, Journal of Biological Chemistry 2457 (1979) 3170–3175.
[11] H. Aebi, Methods in Enzymology 105 (1984) 121–126.
[12] V.R. De Vore, B.E. Greene, Journal of Food Science 47 (1982) 1406–1409.
[13] A. Günzler, L. Flohé, in: R.A. Greenwald (Ed.), CRC Handbook of Methods for Oxygen Radical Research, vol. 1, CRC Press Inc., Boca Raton, FL, USA, 1985, pp. 285–290.
[14] I. Calberg, B. Mannervik, Journal of Biological Chemistry 250 (1975) 5475–5480.
[15] F. López-Neblina, A.J. Paez, L.H. Toledo-Pereyra, Transplantation Proceedings 27 (1995) 1883–1885.
[16] K.K. Donnahoo, X. Meng, A. Ayala, M.P. Cain, A.H. Harken, D.R. Meldrum, American Journal of Physiology 277 (1999) R922–R929.
[17] G.A. Tanner, Kidney International. Supplement 6 (1976) S65–S73.
[18] C.E. Vaca, J. Wilhelm, M. Harms-Ringdahl, Mutation Research 195 (1988) 137–149.
[19] J.M. McCord, American Journal of Medicine 108 (2000) 652–659.
[20] M. Kurata, M. Suzuki, N.S. Agar, Comparative Biochemistry and Physiology – Part B 106 (1993) 477–487.
[21] A. Gurel, F. Armutcu, A. Cihan, K.V. Numanoglu, M. Unalacak, European Surgical Research 36 (2004) 206–209.
[22] E. Mashiach, S. Sela, T. Weinstein, H.I. Cohen, S.M. Shasha, B. Kristal Mesna, Nephrology, Dialysis, Transplantation 16 (2001) 542–551.
[23] A. Korkmaz, D. Kolankaya, Renal Failure 31 (2009) 36–43.
[24] E.H. Bae, K.S. Lee, J. Lee, S.K. Ma, N.H. Kim, K.C. Choi, J. Frøkiaer, S. Nielsen, S.Y. Kim, S.Z. Kim, S.H. Kim, S.W. Kim, American Journal of Physiology. Renal Physiology 294 (2008) F272–F280.
[25] T. Aktoz, N. Aydogdu, B. Alagol, O. Yalcin, G. Huseyinova, I.H. Atakan, Renal Failure 29 (2007) 535–542.
[26] A.V. Ozcan, M. Sacar, H. Aybek, F. Bir, S. Demir, G. Onem, I. Goksin, A. Baltalarli, N. Colakoglu, Journal of Surgical Research 140 (2007) 20–26.